

**PATIENT**

Ghost DeJesus

**SPECIES**

Feline

**BREED**

**SEX**

**AGE**

years

**WEIGHT**

kg

**INTERPRETED BY**

Remo Lobetti, BVSc,  
MMedVet (Med),  
PhD, Dipl. ECVIM

**IMAGING PERFORMED BY**

Seth Mitchell, DVM

**HOSPITAL NAME**

Treasure Coast  
Animal Emergency

**REFERRING VET**

Dr Cail

**INVOICE**

302892

**DATE**

4/8/22

**PRESENTING CLINICAL SIGNS**

History: N/A.

Physical Examination: N/A.

Urinalysis: N/A.

CBC: N/A.

Serum Biochemistry: N/A.

Radiographic Findings: N/A.

**ULTRASONOGRAPHIC EXAMINATION OF THE ABDOMEN**

**Urinary System**

Small urinary bladder with a normal appearance and thickness of the wall. Normal anechoic urine with no sediment or uroliths evident.

Normal trigone area, proximal urethra, and iliac blood vessels.

Normal iliac lymph nodes. Ureters not visualized.

Normal renal size (left 3.4 cm), echogenic appearance, cortico-medullary differentiation, pelvis and capsule.

**Reproductive System**

N/A.

**Adrenal Glands**

Normal shape, echogenic appearance, position, and size.

**Spleen**

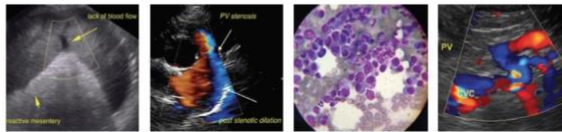
Enlarged (1.6 cm) with a diffuse mottled echogenic appearance. Smooth homogenous parenchyma, curvi-linear capsule, and normal vasculature.

**Liver**

Normal size, echogenic appearance and portal markings. No nodules or masses evident. Full gall bladder containing normal anechoic bile. Normal thickness and echogenic appearance of the gall bladder wall. Normal bile duct.

**Gastrointestinal**

Normal appearance of the gastro-esophageal junction, stomach, duodenum, small intestine, ileo-cecal junction, and colon with no loss of layering, normal wall thickness) and peristalsis, and no distension of the lumen.



**PATIENT**

Ghost DeJesus

**SPECIES**

Feline

**BREED**

**SEX**

**AGE**

years

**WEIGHT**

kg

**INTERPRETED BY**

Remo Lobetti, BVSc,  
MMedVet (Med),  
PhD, Dipl. ECVIM

**IMAGING  
PERFORMED BY**

Seth Mitchell, DVM

**HOSPITAL NAME**

Treasure Coast  
Animal Emergency

**REFERRING VET**

Dr Cail

**INVOICE**

302892

**DATE**

4/8/22

***Pancreas***

Normal size and echogenic appearance. Regular capsule. Normal echogenic appearance of the mesentery and fat surrounding the pancreas.

***Free Abdomen***

No mesenteric lymphadenomegaly.  
No ascites.

***Thorax***

Normal appearance of the heart with normal contraction.  
No pericardial or pleural effusion

**ULTRASONOGRAPHIC FINDINGS**

Primary findings:

- Splenomegaly.

Secondary findings:

- None.

**INTERPRETATION OF THE FINDINGS & FURTHER RECOMMENDATIONS**

Etiologies for the splenomegaly would be reactive, hyperplasia, splenitis, and infiltrative neoplasia (lymphoma, mast cell).

Initial further assessment would be FNA cytology of the spleen.

Specific therapy would be dependent on an etiological diagnosis.



**PATIENT**

Ghost DeJesus

**SPECIES**

Feline

**BREED**

**SEX**

**AGE**

years

**WEIGHT**

kg

**INTERPRETED BY**

Remo Lobetti, BVSc,  
MMedVet (Med),  
PhD, Dipl. ECVIM

**IMAGING PERFORMED BY**

Seth Mitchell, DVM

**HOSPITAL NAME**

Treasure Coast  
Animal Emergency

**REFERRING VET**

Dr Cail

**INVOICE**

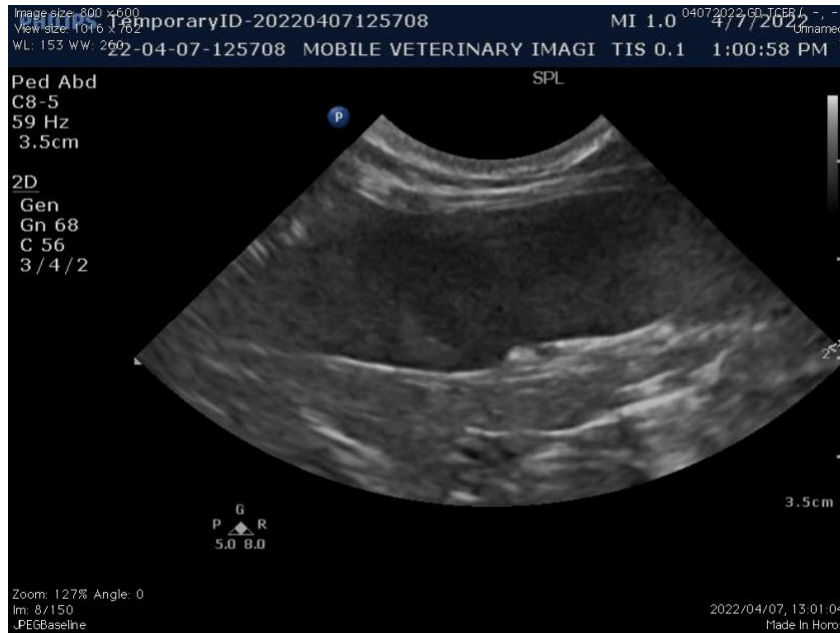302892

**DATE**

4/8/22

**IMAGES**

**Spleen**



The information and recommendations provided are based on the images presented by the referring veterinarian. No evaluation can be communicated regarding pathology that was not visible in the image/video clips provided.

Thank you for this referral. If the clinical or image interpretation does not parallel your findings or if I can be of any further assistance please contact me.

**Remo Lobetti, BVSc, MMedVet (Med), PhD, Dipl. ECVIM (Internal Medicine)**  
rlobetti@mweb.co.za